

# Static or Dynamic Navigation for Implant Placement—Choosing the Method of Guidance

Michael S. Block, DMD,\* and Robert W. Emery, DDS†

The purpose of the present report is to contrast and compare 2 methods of dental implant placement. One method uses computed tomography data for computer-aided design and computer-aided manufacturing to generate static guides for implant placement. The second method is a dynamic navigation system that uses a stereo vision computer triangulation setup to guide implant placement. A review of the published data was performed to provide evidence-based material to compare each method. Finally, the indications for each type of method are discussed.

© 2016 American Association of Oral and Maxillofacial Surgeons  
*J Oral Maxillofac Surg* 74:269-277, 2016

## Clinical Problem

Dental implants need to be placed accurately at the proper depth, angulation, and crestal position. The traditional methods to place implants have used free hand or limited guidance from laboratory-fabricated stents. The use of a static, computed tomography (CT)-generated guide stent with a coordinated system of specified drilling can result in less than 2 mm crestal and apical deviation from the plan and an angulation error of less than 5°. <sup>1-8</sup> Freehand methods for implant placement result in significantly more error compared with navigation methods. <sup>7</sup> CT-generated static stents have workflow time and cost considerations. Dynamic navigation uses a time-effective method to accurately place implants with equivalent implant placement error. The question for the clinician is when to use a static system or a dynamic navigation system.

The costs of using CT-generated static stents include the cost of the software and the cost for fabrication of the CT-generated guide stent. The costs for the dynamic navigation system include the navigation computer system, including the arrays. Recurring costs include the cost of the patient-specific clips, although that cost is relatively inexpensive.

Why should clinicians consider static or dynamic navigation? Navigation can result in accurate depth

control and should decrease the risk of damage to the inferior alveolar nerve. Navigation also allows for flapless or limited flap elevation, resulting in less post-operative morbidity to the patient. Navigation with virtual implant placement provides accurate spacing and angulation of the implants compared with the use of free-hand approaches. Virtual implant planning and navigated placement can ensure appropriate implant angulation and depth for esthetic situations. The use of virtual implant planning and subsequent navigation also allows for prosthetic and surgical collaboration with precise planning and accurate orchestration of the plan to achieve a high level of patient-specific results. However, both static and dynamic navigation systems have limitations, as we discuss.

## Static Guides

A static system uses CT-generated computer-aided design and computer-aided manufacturing to create stents, with metal tubes, and a surgical system that uses coordinated instrumentation to place implants using the guide stent (Fig 1). The implant position is dependent on the stent without the ability to change the implant position (Fig 2). “Static” in this sense is synonymous with a predetermined implant position without real-time visualization of the implant preparation site

\*Private Practice, Metairie, LA.

†Private Practice, Washington, DC.

Conflict of Interest Disclosures: Dr Emery is Chief Medical Officer of X-Nav Technologies LLC and, has equity interest in the company.

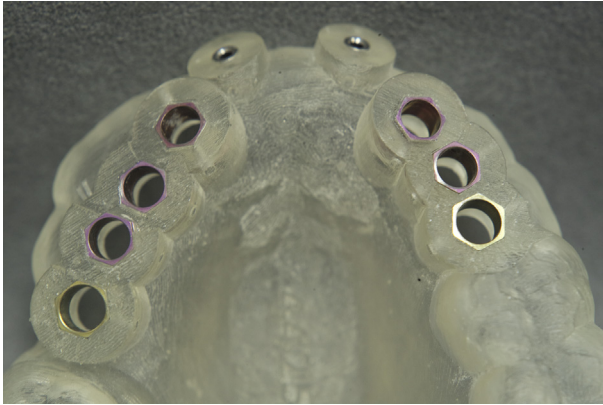
Address correspondence and reprint requests to Dr Block: 110 Veterans Memorial Blvd, Suite 112, Metairie, La 70005; e-mail: [drblock@cdrnola.com](mailto:drblock@cdrnola.com)

Received May 25 2015

Accepted September 18 2015

© 2016 American Association of Oral and Maxillofacial Surgeons  
 0278-2391/15/01290-2

<http://dx.doi.org/10.1016/j.joms.2015.09.022>

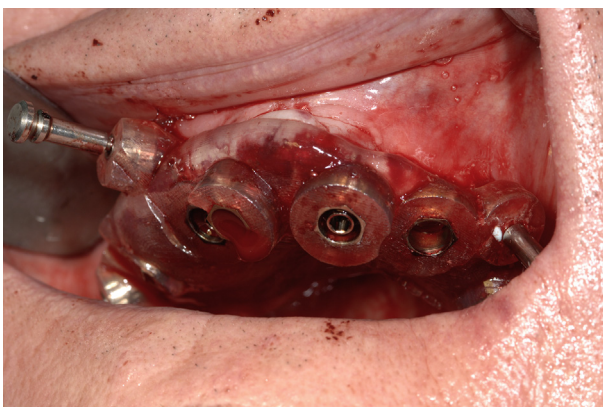


**FIGURE 1.** Computed tomography-generated static guide for an edentulous patient.

*Block and Emery. Guidance Method for Implant Placement. J Oral Maxillofac Surg 2016.*

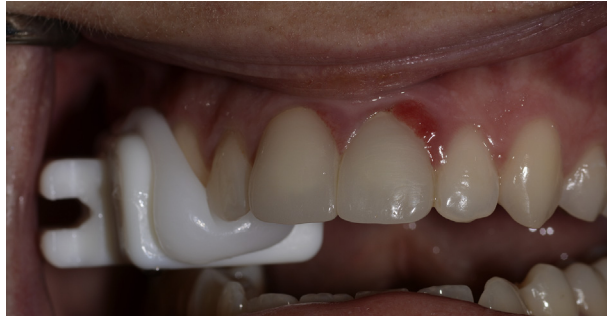as it is developed. No intraoperative position changes can be made using a static system unless use of the stent is abandoned during the surgical procedure.

To fabricate a CT-generated surgical guide (Fig 1) for static navigation, a cone-beam CT scan (CBCT) is taken with the prosthetic plan in the mouth as an imaging guide. Fabrication of the imaging guide requires laboratory work before scanning, which will necessitate time delays and additional cost to the team and, hence, added cost to the patient. Future digital methods might eliminate the need for the laboratory-based imaging guide. The CBCT Digital Imaging and Communications in Medicine (DICOM) data must be entered into the CT planning software. The use of the CT planning software requires training to use the software. Many clinicians will not learn the software proficiently and might decide to use a third party to plan the case. After the team has finalized the plan, the plan will be uploaded



**FIGURE 2.** Multiple implants in predetermined positions as directed by the computed tomography-generated static guide. The guide allowed for accurate implant placement; however, no changes in the plan could be performed with guidance owing to the static nature of the guide stent.

*Block and Emery. Guidance Method for Implant Placement. J Oral Maxillofac Surg 2016.*



**FIGURE 3.** Clip with fiducials placed in the patient's mouth before cone-beam computed tomography scanning. The fiducial markers allow for registration of the patient's maxilla for triangulation during the implant placement procedure.

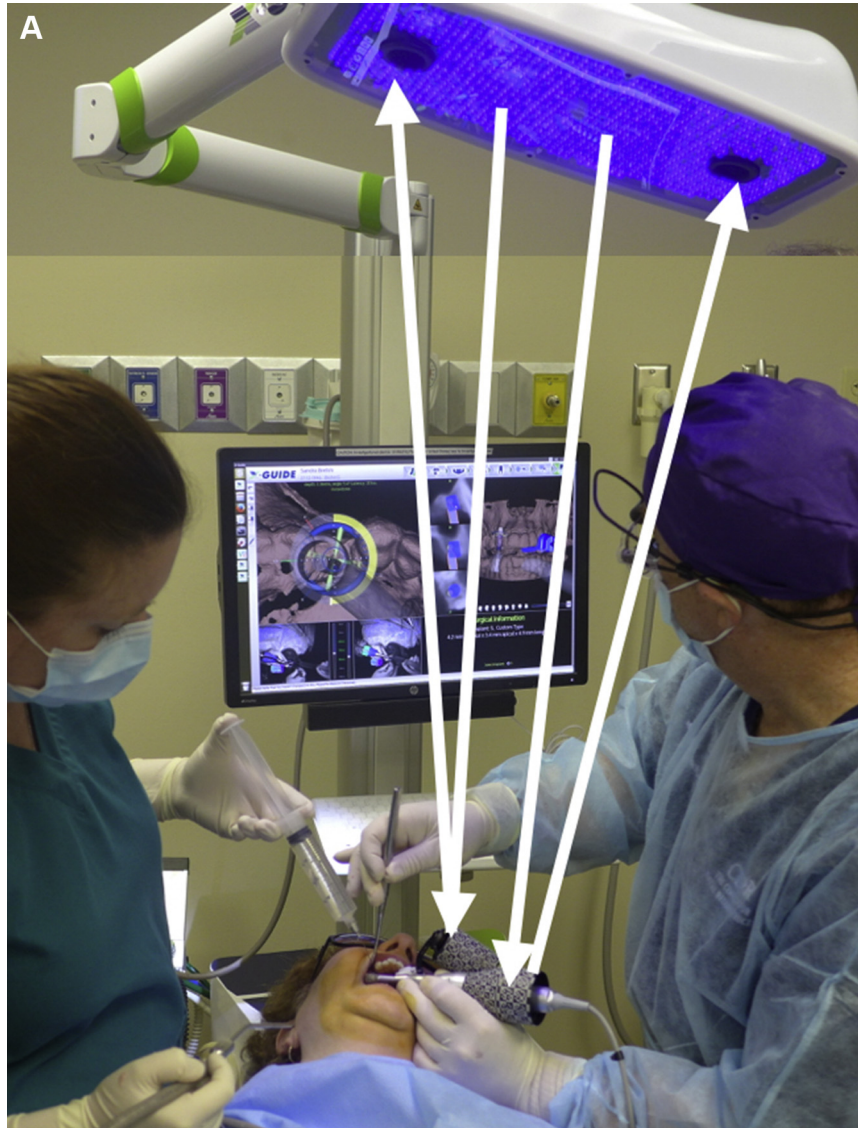
*Block and Emery. Guidance Method for Implant Placement. J Oral Maxillofac Surg 2016.*

to the stent manufacturer. A model or an optical scan of the arch is needed to fabricate a guide that will seat accurately on the teeth. This requires impressions, pouring stone, and trimming the model. All these requirements add time and costs to the CT-guided static method. The manufacturer will evaluate the uploaded scan and determine whether it meets the quality control parameters. The clinician might need to repeat the process if the static guide does not seat accurately on the teeth or tissues. The period between upload and delivery of the guide stent can require 2 weeks. Once the guide stent has been delivered, the surgery can be performed. The cost for static CT-generated guides will differ between manufacturers. These require preoperative procedures and their added cost, combined with the clinician's reluctance to gain proficiency with the planning software, creates a workflow barrier for the use of static CT-generated guides.

When using a CT static guide, the surgeon will require the appropriate surgical kit specific to the implant system. The implant choice cannot be easily changed once the CT guide stent has been fabricated. Thus, during surgery, the implant placement position cannot be changed unless the surgeon abandons the use of the CT guide stent. The use of the CT-generated guide stent also limits the ability to irrigate the drill during the process, because access is limited to the bone, with the potential for increased heat production.<sup>9</sup>

The use of static guides is difficult when the patient has limited mouth opening and when placement is required in the second molar regions. When prolongation for accurate depth determination is added to the drill length, the combined length will often exceed the patient's maximal mouth opening. This problem will be most evident in the posterior region of the mouth.

The advantages of using a static CT-generated guide stent include accurate implant placement, the use of a flapless approach, and the ability to use the guide stent



**FIGURE 4.** A, Overhead lights emitting blue lights, which are reflected back to 2 cameras by the arrays on the clip in the patient's mouth and on the handpiece. (Fig 4 continued on next page.)

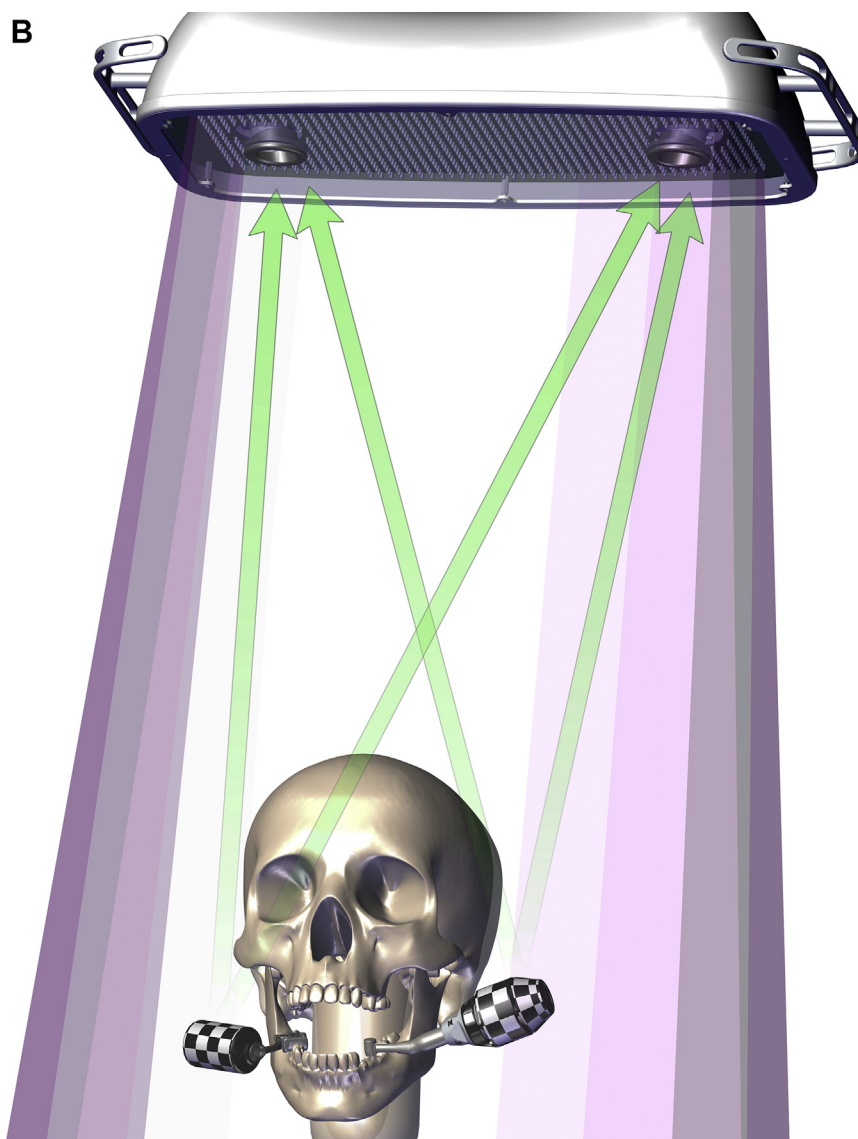
*Block and Emery. Guidance Method for Implant Placement. J Oral Maxillofac Surg 2016.*

to preoperatively fabricate fixed provisional restorations. Also, in general, the use of static CT-generated stents requires less-invasive surgery, which results in less patient morbidity.

### Dynamic Navigation

At present, the dynamic navigation systems available for dental implant placement use optical technologies to track the patient and the hand piece and to display images onto a monitor.<sup>10,11</sup> The optical systems use either passive or active tracking arrays. Passive systems use tracking arrays that reflect light emitted from a light source back to the stereo cameras. Active system arrays emit light that is tracked by stereo cameras.

A passive optical dynamic navigation system (X-Nav Technologies, Inc, Lansdale, PA) requires the use of fiducial markers securely attached to the patient's arch during CBCT scanning (Fig 3). The device that contains the fiducial markers allows for registration of the arch to the cameras, with the attachment of an array. The array is positioned extraorally and attached to the clip that contains the fiducial markers. The implant handpiece also has an array, which combined with the clip's fiducial markers, allows for triangulation and, hence, accurate navigation (Fig 4). The drill and patient-mounted arrays must be within the line of sight of the overhead stereo cameras to be accurately tracked on the monitor.<sup>12-20</sup> A small flap can be made, as needed, to expose the crestal bone. The



**FIGURE 4 (cont'd).** B, Line drawing depicting the emitted light from the blue lights in the overhead array, which are then reflected back to the 2 cameras in the overhead array. The 3-dimensional graphics are then displayed on the navigation screen.

*Block and Emery. Guidance Method for Implant Placement. J Oral Maxillofac Surg 2016.*

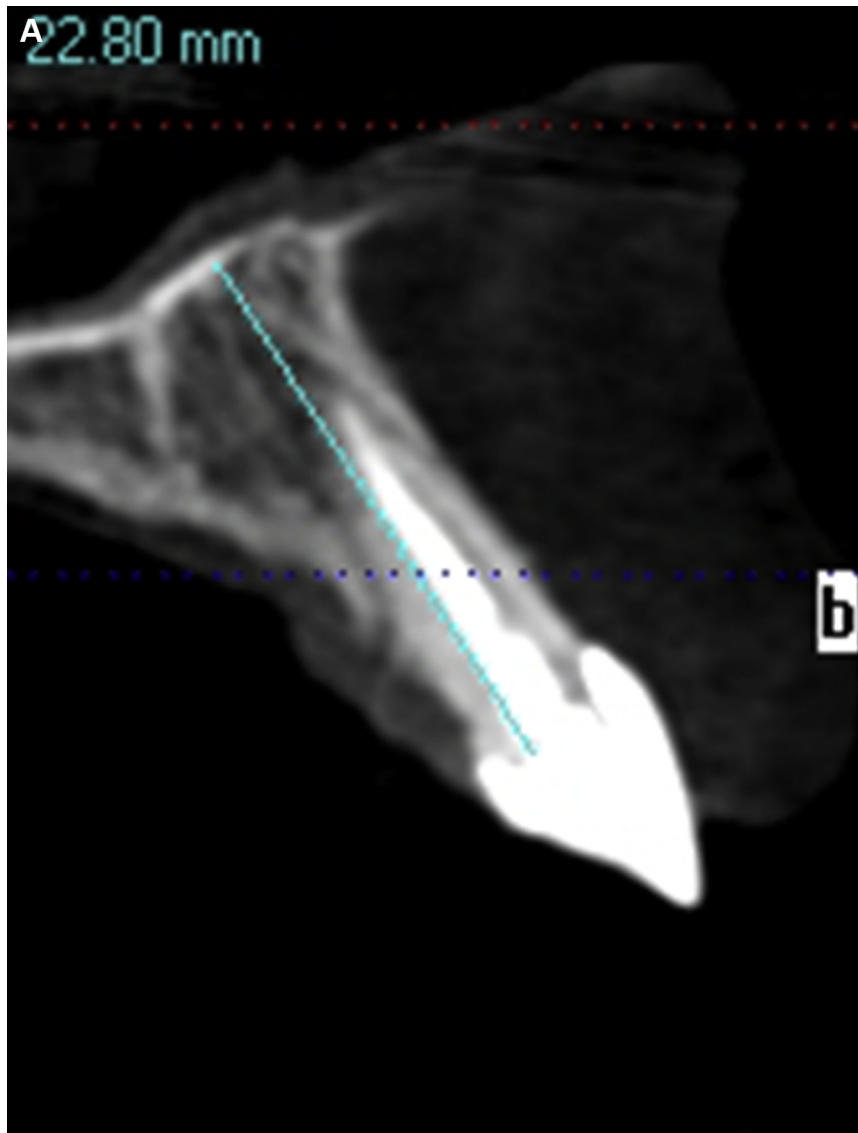
normal implant site drilling protocol is used. The surgeon uses the navigation screen to guide the drilling, with minimal direct visualization of the drill in the patient's mouth.

The workflow for dynamic navigation begins with securing the fiducial markers to the arch. A clip that contains 3 metallic fiducial markers is fit onto the patient's teeth in an area that will not undergo surgery. If an esthetic plan will be used, radiopaque teeth can be included in the mouth as an imaging guide to allow for later virtual implant positioning. The CBCT scan should be taken with the clip in place. The clip can then be removed and stored for use during the surgery.

The DICOM data set is loaded into the navigation system's computer. A virtual implant is then placed.

The software is simple and requires minimal computer experience by the clinician. The implants are generically generated using the platform diameter, apical diameter, and length in 0.1-mm increments. The implant can be oriented as needed.

At surgery, the clip with the fiducial markers is attached to an array. The clip with the attached array and the handpiece with similar arrays should be registered to the navigation system by the staff. The surgeon can use traditional anesthesia and small incisions, with minimal flap reflection. The clip array should be securely repositioned onto the arch. The drill lengths should have been registered during the preparation process. The surgeon then positions the patient and arrays for direct line of sight to the overhead cameras.



**FIGURE 5.** Cross-sectional images showing the A, preoperative view, (**Fig 5 continued on next page.**)

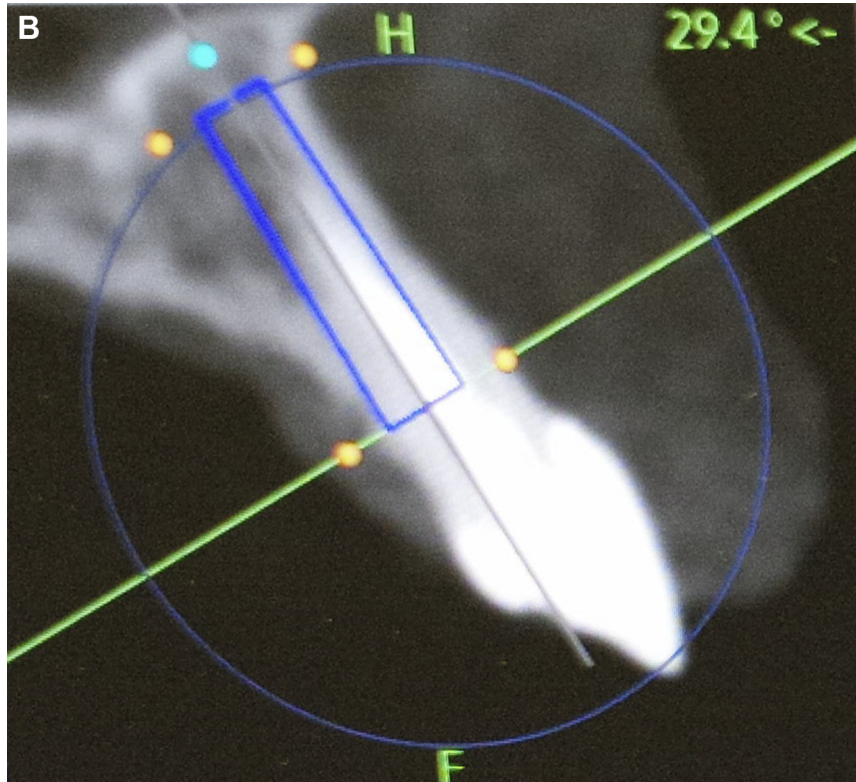
*Block and Emery. Guidance Method for Implant Placement. J Oral Maxillofac Surg 2016.*

The drills should be oriented in accordance with the 3-dimensional images on the screen, which includes the depth. The surgical assistant should focus on the irrigation, retraction, and suctioning, as usual. The implant can be placed fully or partially guided by hand, depending on clinician preference (Fig 5).

The advantages of the dynamic navigation method include its accuracy,<sup>21-24</sup> time- and cost-effectiveness, and the ability to change the implant size, system, and location during the surgical procedure. It also requires less-invasive flap reflection compared with free-hand approaches and results in less trauma to the surgeon because the surgeon's posture is improved, with less back and neck bending. In a patient who has difficulty with mouth opening or re-

quires an implant at a second molar site, which can be difficult to access, dynamic navigation allows for implant placement by relying on the navigation screen to guide the drills without direct visualization in the patient's mouth.

A variable learning curve exists for developing proficiency using a dynamic navigation system. The medical data have reported that 15 to 125 case experiences can be required, depending on the procedure and the use of surgical simulators, before clinicians will have developed proficiency with new surgical procedures.<sup>25,26</sup> Dynamic navigation also requires a team approach. Both the surgeon and the first assistant must learn to work together for efficient use of a dynamic navigation system.



**FIGURE 5 (cont'd).** B, virtual plan, and (Fig 5 continued on next page.)

*Block and Emery. Guidance Method for Implant Placement. J Oral Maxillofac Surg 2016.*

## Accuracy Considerations

### STATIC CT-GENERATED GUIDES

The use of CT-generated guide stents results in more accurate implant placement compared with that of free-hand or model-based nonrestricted guides, including for the apical and platform positions and depth control.<sup>1,2</sup> CT-generated guides do have a measurable error associated with them. Depending on the use of mucosa- or tooth-supported guides, the deviations have ranged from 0.6 to 1.5 mm at the implant apex to 0.6 to 1.27 mm at the shoulder. Implant angulation deviations from the plan ranged from 2.5 to 5°. More than one half will be placed more superficially than planned.<sup>3-6</sup>

The accuracy using static CT-generated guides differs from clinician to clinician. Some clinicians will be more accurate with CT-guided implant placement than others. A statistically significant difference was noted comparing surgeons regarding the positions of the apex, depth, and angle.<sup>6</sup> When inexperienced surgeons were supervised by experienced surgeons, no significant difference was found between the inexperienced and experienced surgeons regarding implant placement accuracy using CT-generated stent use.<sup>6</sup>

Comparing guided surgery (mucosa and bone supported) and free-hand implant placement or the use

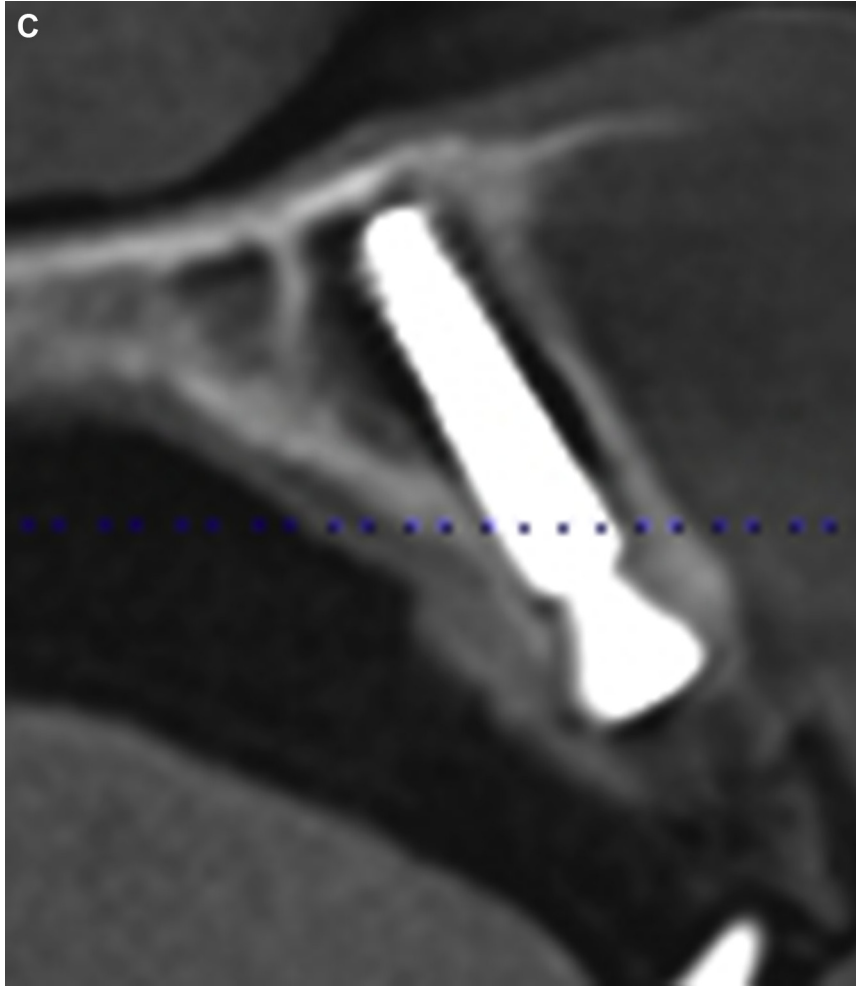
of a surgical template in fully edentulous jaws, the guided implant placement group deviation at the entry point was 1.4 mm, the apical deviation was 1.6 mm, and the angular deviation was 3.0°. The deviation with free-hand methods was 2.7 mm at the entry, 2.9 mm at the apex, and 9.9° of angular deviation. The CT-generated guided methods resulted in placement closer to the virtual plan.<sup>7</sup>

### DYNAMIC NAVIGATION SYSTEM

The results from studies by Chiu et al,<sup>21</sup> Kramer et al,<sup>22</sup> Brief et al,<sup>23</sup> and Casap et al<sup>24</sup> have indicated that dynamic navigation systems have an entry error approximating 0.4 mm and an angular deviation error approximating 4°. Clinical studies have been limited, but have reported implant success rates similar to that of conventional drilling methods.<sup>27-30</sup>

## Indications for Each Method

For some clinical situations, either method will be advantageous compared with the freehand method. The choice of static or dynamic navigation will depend on the clinician's preference and experience. Thus, either navigation method can be used for the following:



**FIGURE 5 (cont'd).** C, actual postoperative cross-section with the implant in place. The implant site was prepared using the dynamic navigation system and placed under guidance.

*Block and Emery. Guidance Method for Implant Placement. J Oral Maxillofac Surg 2016.*

1. The clinician wishes to use a flapless approach because the site has undergone previous ridge augmentation and the clinician wants to avoid disturbing the superficial part of the graft with flap elevation.
2. When placement of adjacent implants requires accurate spacing between the implants and adjacent teeth; using a navigation system will ensure appropriate spacing of the implants from the teeth and provide accuracy in maintaining the appropriate space between the implants.
3. When accurate implant angulation is required, which is especially important in the esthetic zone and for screw-retained prostheses.
4. To control the depth placement.
  - a. To avoid nerve trauma.
  - b. To place the preparation osteotomy adjacent to the sinus floor when elevating the sinus floor through the implant preparation site.
  - c. To intentionally engage the floor of the sinus or nasal floor for bicortical implant stability.

A CT-generated static guide is recommended for edentulous cases. Dynamic navigation requires registration of the jaw to the navigation system, which currently cannot use intrabony fiducial markers. For edentulous cases, a static CT-generated guide should be used when:

1. A flapless method is desired.
2. The CT-generated guide can be used to preoperatively fabricate a provisional prosthesis on models generated from the static guide itself.
3. The clinician desires the use of a bone reduction guide to accurately provide space for the planned prosthesis.
4. Implant placement is critical for a planned full arch fixed crown and bridge type prosthesis.

However, dynamic navigation is indicated for any of the following:

1. Placement of implants in patients with a limited mouth opening.
2. Placement of the implant on the same day of the CBCT scan.
3. Placement of implants in difficult-to-access locations such as the second molar.
4. Placement of implants when direct visualization will be difficult.
5. Placement of implants in tight interdental spaces when static guides cannot be used owing to tube size.
6. Placement of implants adjacent to natural teeth in situations in which static guide tubes will interfere with ideal implant placement.

## General Considerations

For specific situations, the choice of which method will be best will be clear. As the experience of the clinician and their surgical proficiency increases, the use of the dynamic method might predominate, because of the time- and cost-efficient workflow.

In dentate patients, dynamic navigation requires the presence of teeth to stabilize the registration clip and array. The registration and clip array should not be placed on temporarily cemented provisional restorations or on mobile teeth.

Also, placement of implants in molar locations with difficult direct visual access occurs in patients with a limited mouth opening or crestal bone loss, resulting in the need for drill extenders. Placement of adjacent implants requires accurate spacing between the implants and adjacent teeth. Static or dynamic systems can each be used; however, the selection will depend on clinician experience and case-specific considerations.

Dynamic navigation is flexible, allowing the clinician to change the surgical plan as the clinical situation dictates. It also requires no laboratory work, thus allowing for immediate scanning, planning, and guidance on the same day as patient presentation. The clinician must understand that a learning curve is required to gain proficiency. This could require additional time for training, simulation, and practice on a manikin.

## References

1. Scherer U, Stoetzer M, Ruecker M, et al: Template-guided vs. non-guided drilling in site preparation of dental implants. *Clin Oral Investig* 19:1339, 2015

2. Noharet R, Pettersson A, Bourgeois D: Accuracy of implant placement in the posterior maxilla as related to 2 types of surgical guides: A pilot study in the human cadaver. *J Prosthet Dent* 112:526, 2014
3. Beretta M, Poli PP, Maiorana C: Accuracy of computer-aided template-guided oral implant placement: A prospective clinical study. *J Periodontal Implant Sci* 44:184, 2014
4. Zhao XZ, Xu WH, Tang ZH, et al: Accuracy of computer-guided implant surgery by a CAD/CAM and laser scanning technique. *Chin J Dent Res* 17:31, 2014
5. Pettersson A, Kero T, Söderberg R, Näsström K: Accuracy of virtually planned and CAD/CAM-guided implant surgery on plastic models. *J Prosthet Dent* 112:1472, 2014
6. Van de Wiele G, Teughels W, Vercruyssen M, et al: The accuracy of guided surgery via mucosa-supported stereolithographic surgical templates in the hands of surgeons with little experience. *Clin Oral Implants Res*, 2014 Oct 16. <http://dx.doi.org/10.1111/clr.12494>. [Epub ahead of print]
7. Vercruyssen M, Cox C, Coucke W, et al: A randomized clinical trial comparing guided implant surgery (bone- or mucosa-supported) with mental navigation or the use of a pilot-drill template. *J Clin Periodontol* 41:717, 2014
8. Ozan O, Turkyilmaz I, Ersoy AE, et al: Clinical accuracy of 3 different types of computed tomography-derived stereolithographic surgical guides in implant placement. *J Oral Maxillofac Surg* 67:394, 2009
9. dos Santos PL, Queiroz TP, Margonar R, et al: Evaluation of bone heating, drill deformation, and drill roughness after implant osteotomy: Guided surgery and classic drilling procedure. *Int J Oral Maxillofac Implants* 29:51, 2014
10. Nijmeh AD, Goodger NM, Hawkes D, et al: Image-guided navigation in oral and maxillofacial surgery. *Br J Oral Maxillofac Surg* 43:294, 2005
11. Bouchard C, Magil JC, Nikonovskiy V, et al: Osteomark: A surgical navigation system for oral and maxillofacial surgery. *Int J Oral Maxillofac Surg* 41:265, 2012
12. Strong EB, Rafii A, Holhweg-Majert B, et al: Comparison of 3 optical navigation systems for computer-aided maxillofacial surgery. *Arch Otolaryngol Head Neck Surg* 134:1080, 2008
13. Casap N, Wexler A, Eliashar R: Computerized navigation for surgery of the lower jaw: Comparison of 2 navigation systems. *J Oral Maxillofac Surg* 66:1467, 2008
14. Poeschl PW, Schmidt N, Guevara-Rojas G, et al: Comparison of cone-beam and conventional multislice computed tomography for image-guided dental implant planning. *Clin Oral Investig* 17:317, 2013
15. Ewers R, Schicho K, Undt G, et al: Basic research and 12 years of clinical experience in computer-assisted navigation technology: A review. *Int J Oral Maxillofac Surg* 34:1, 2005
16. Wittwer G, Adeyemo WL, Schicho K, et al: Prospective randomized clinical comparison of 2 dental implant navigation systems. *J Oral Maxillofac Implant* 22:785, 2007
17. Wanschitz F, Birkfellner W, Watzinger F, et al: Evaluation of accuracy of computer-aided intraoperative positioning of endosseous oral implants in the edentulous mandible. *Clin Oral Implants Res* 13:59, 2002
18. Lueth TC, Wenger T, Rautenberg A, Deppe H: RoboDent and the change of needs in computer aided dental implantology during the past ten years. Presented at the 2011 IEEE International Conference on Robotics and Automation, May 9-13, 2011. *IEEE Abstracts* 2011:1
19. Casap N, Laviv AW: Computerized navigation for immediate loading of dental implants with a prefabricated metal frame: A feasibility study. *J Oral Maxillofac Surg* 69:512, 2011
20. Siessegger M, Schneider BT, Mischkowski RA, et al: Use of an image-guided navigation system in dental implant surgery in anatomically complex operation sites. *J Craniomaxillofac Surg* 29:276, 2001
21. Chiu WK, Luk WK, Cheung LK: Three-dimensional accuracy of implant placement in a computer-assisted navigation system. *J Oral Maxillofac Implant* 21:465, 2006



22. Kramer FJ, Baethge C, Swennen G, Rosahl S: Navigated vs. conventional implant insertion for maxillary single tooth replacement. *Clin Oral Implants Res* 16:60, 2005
23. Brief J, Edinger D, Hassfeld S, Eggers G: Accuracy of image-guided implantology. *Clin Oral Implants Res* 16:495, 2005
24. Casap N, Wexler A, Persky N, et al: Navigation surgery for dental implants: Assessment of accuracy of the image guided implantology system. *J Oral Maxillofac Surg* 62:116, 2004
25. Arora KS, Khan N, Abboudi H, et al: Learning curves for cardiothoracic and vascular surgical procedures—A systematic review. *Postgrad Med* 127:202, 2015
26. Koch AD, Ekkelenkamp VE, Haringsma J, et al: Simulated colonoscopy training leads to improved performance during patient-based assessment. *Gastrointest Endosc* 81:630, 2015
27. Wittwer G, Adeyemo WL, Schicho K, et al: Computer-guided flapless transmucosal implant placement in the mandible: A new combination of two innovative techniques. *Oral Surg Oral Med Oral Pathol Oral Radiol Endod* 101:718, 2006
28. Hultin M, Svensson KG, Trulsson M: Clinical advantages of computer-guided implant placement: A systematic review. *Clin Oral Implants Res* 23(suppl 6):124, 2012
29. Wittwer G, Adeyemo WL, Wagner A, Enislidis G: Computer-guided flapless placement and immediate loading of four conical screw-type implants in the edentulous mandible. *Clin Oral Implants Res* 18:534, 2007
30. Jung RE, Schneider D, Ganeles J, et al: Computer technology applications in surgical implant dentistry: A systematic review. *Int J Oral Maxillofac Implants* 24(suppl):92, 2009